



## PATIENT

Onyae Allred

## PRESENTING CLINICAL SIGNS

History: Grade 2/6 heart murmur. Assess prior to dental.

## SPECIES

Feline

## ELECTROCARDIOGRAPHIC FINDINGS

A six lead ECG is available at 25mm/s; 20 and 40mm/mV. Low voltage complexes despite increased sensitivity. What can be said is the heart rate is 214bpm with a largely regular rhythm. No obvious dysrhythmias are observed. Complex morphology, MEA, etc. cannot be commented on.

## BREED

DSH

ECG diagnosis: Normal sinus tachycardia.

## SEX

Female Spayed

## ECHOCARDIOGRAM FINDINGS

2D, m-mode, color flow and doppler imaging is available. The left ventricular wall is normal in dimension. There is a diffusely hyperechoic endocardium consistent with age-related fibrosis. Minimal remodeling. The papillary muscles are hyperechoic. The left atrium is normal in size. The right atrium is normal in size. The right ventricle appears normal. The mitral valve is normal in structure and mobility. No MR. The tricuspid valve appears normal in structure and mobility. No TR. Blood flow through both the LVOT and RVOT are normal in velocity. No effusions. No obvious cardiac tumors.

## AGE

12 years

## CARDIAC CHART

## WEIGHT

9.8lbs

## INTERPRETED BY

Maggie Machen Lamy,  
DVM, DACVIM  
(Cardiology)

FELINE CARDIAC PARAMETERS	BODY WEIGHT (kg)	HR (BPM)	IVSd (cm) (Moise, Pipers)	LVIDd (cm) (Moise, Pipers)	LWVd (cm) (Moise, Pipers)	FS (%)	EF (%)
NORMAL PARAMETER	-----	150-240	0.35-0.55	<2 (mean 1.5)	3.5-0.55	35-67	80-100
PATIENT	4.4	NM	0.41	1.0	0.35	70	97
FELINE CARDIAC PARAMETERS	LA/AO (Boon)	LA/AO HEART BASE (Swe) (Abbott)	LA 2D short axis Base view (cm) (Abbott)		LVOT VEL (m/s)	RVOT VEL (m/s)	E max (m/s)
NORMAL	<1.5	<1.3	<1.2		<1.6	<1.3	<0.9
PATIENT	1.0	1.2	1.2		1.0	0.9	NM

\*Note: All measurements based upon multi-modal images and methods. An average value is reported.

Adapted from June Boon, Veterinary Echocardiography, 1998

Abbott J & MacLean H JVIM 2006;20: 111-119, Moise et al. Am J Vet Res 47:1476, 1986. Pipers et al. Am J Vet Res 40:882, 1979.

## IMAGING PERFORMED BY

Dana Alterman,  
RDMS, LVT

## HOSPITAL NAME

Eubank Animal Clinic

## REFERRING VET

Dr. Pauly

## INTERPRETATION OF THE FINDINGS & FURTHER RECOMMENDATIONS

Overtly normal geriatric cardiac structure and function. Mild fibrosis of the left ventricular wall is noted, which is likely a normal age-related variant. No significant valve leaks are noted, and flow through the great vessels is normal in velocity. No definitive cause is identified for the murmur in this study, making it likely physiologic in origin (i.e., secondary to tachycardia, volume changes, etc.). Given these findings and a normal LA dimension, no medications are indicated. The ECG is unremarkable with a normal sinus tachycardia.

## INVOICE

32067

No cardiac contraindication for general anesthesia. Should fluid or steroid therapy be indicated in the future, any cat should be monitored for intolerance (changes in RR/RE).

## DATE

8/1/23



**PATIENT**

Onyae Allred

Monitor at home for signs of cardiac compromise, including respiratory changes and/or signs of a blood clot event (paralysis, neurologic changes).

**SPECIES**

Feline

Recommend recheck echocardiogram in 1 year to assess for any progressive issues or development of disease the pre-existing murmur may mask.

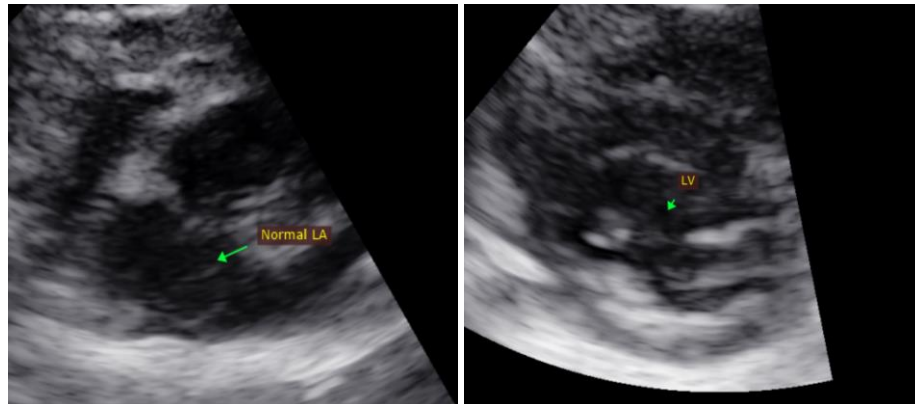
**BREED**

DSH

**SEX**

Female Spayed

**IMAGES**

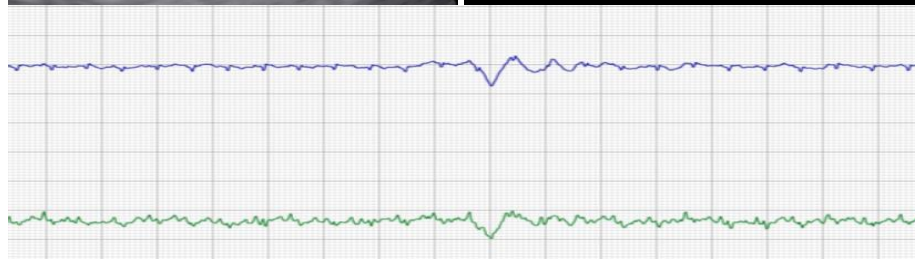

**AGE**

12 years

**WEIGHT**

9.8lbs



**INTERPRETED BY**

Maggie Machen Lamy,  
DVM, DACVIM  
(Cardiology)

The information and recommendations provided are based on the images presented by the referring veterinarian. No evaluation can be communicated regarding pathology that was not visible in the image/video clips provided.

**IMAGING PERFORMED BY**

Dana Alterman,  
RDMS, LVT

Thank you for this referral. This report was generated using transcription software, and minor dictation errors may be present. If the clinical or image interpretation does not parallel your findings or if I can be of any further assistance, please contact me.

**HOSPITAL NAME**

Eubank Animal Clinic

**Maggie Machen Lamy, DVM**  
Diplomate of the American College of Veterinary Internal Medicine (Cardiology)  
info@sonopath.com

**REFERRING VET**

Dr. Pauly

**INVOICE**

32067

**DATE**

8/1/23